



A Rare Cause of Intestinal Obstruction: Paraduodenal Hernia

Nadir Bir Ileus Nedeni: Paraduodenal Herni

Mehmet Aziret¹, Enver Reyhan², Hasan Erdem², Selim Sözen³

¹ Adana Numune Training and Research Hospital Department of General Surgery, Adana and Kars State Hospital, Kars

² Adana Numune Training and Research Hospital Department of General Surgery, Adana

³ Namik Kemal University Department of General Surgery, Tekirdağ

Abstract

Internal abdominal hernias may rarely be the cause of intestinal obstruction with an incidence of less than 1% and paraduodenal hernias constitute approximately 50% of them. Those hernias emerge as a result of abnormalities in gut rotation at the embryonic stage. The clinical spectrum of a symptomatic internal hernia may range from abdominal pain to frank intestinal obstruction. Delay in the diagnosis and treatment should be avoided, since the content of paraduodenal hernia may quickly progress to strangulation and necrosis because of vascular compromise. Here, we report a case of successfully diagnosed and treated with cause of paraduodenal hernia.

Key words: Bowel obstruction, internal abdominal hernia, paraduodenal hernia

Özet

İnternal abdominal herniler incebağırsak obstrüksiyonunun nadir görülen bir nedeni olup insidansı %1'den az olarak bildirilmiştir. Paraduodenal herni (PDH) ise, internal hernilerin yaklaşık % 50' sini oluşturmaktadır. Bu herniler bağırsağın rotasyonundaki değişimler nedeniyle oluşmaktadır. Tekrarlayıcı karın ağrılarında, akut bağırsak tıkanıklığına kadar değişebilen klinik spektrumu mevcuttur. PDH' de içeriğin, strangülasyon ve nekrozuna kadar giden dolaşım bozukluğu riski nedeniyle tanı ve tedavi geciktirilmemelidir. Biz burada, ince bağırsak tıkanıklığı nedeniyle ameliyata alınan ve başarılı bir şekilde PDH onarımı yapılan hastayı sunduk.

Anahtar kelimeler: : Bağırsak tıkanıklığı, internal abdominal herni, paraduodenal herni

Introduction

An internal abdominal herniation is the protrusion of an abdominal organ through a normal or abnormal mesentric or peritoneal aperture¹. A Paraduodenal Hernia (PDH) is the most common cause of congenital internal herniation, which occurs as a result of abnormal rotation of the midgut. Fusion defect

of mesentery to posterior parietal peritoneum constitutes a potential hernia orifice².

While internal herniation (IH) constitutes the 1-5% of intestinal obstructions, PDH constitutes about 50% of internal hernias. In men, PDH is 3 times more frequent than in women and the mortality rate is over 20%²⁻⁸.

Corresponding Author / Sorumlu Yazar:

Dr. Mehmet Aziret
Kars State Hospital, Department of General Surgery, Kars
E-mail: mhmtaziret@gmail.com
Tel: +905063057317

Article History / Makale Geçmişi:

Date Received / Geliş Tarihi: 24.04.2014
Date Accepted / Kabul Tarihi: 15.08.2014

The life-time risk of developing obstruction or bowel strangulation is 50%. There are two types of PDH, and left paraduodenal hernias are 3 times more frequent than the right ones^{3,4}. It is difficult to diagnose PDH before surgery. Patients are generally admitted to the hospital with abdominal pain, nausea, vomiting, constipation and distention⁵. Computed tomography (CT) is helpful in diagnosis. In treatment, basic hernia repairs are performed^{6,7}.

We present a patient admitted with abdominal pain, nausea and vomiting, distended abdomen and inability to pass flatus and stool. Said patient underwent operation for small bowel obstruction and PDH was successfully repaired.

Case Report

A 46-year-old, morbidly obese (BMI: 42) male patient with abdominal pain, nausea and vomiting, abdominal distention and inability to pass flatus and stool for 10 days was evaluated in the emergency service area. Patient had no other disease other than hypertension and obesity. He had no previous abdominal surgery. On physical examination, his general condition was moderate and there were hypotension (90/60 mmHg) and tachycardia (106 /minute). Abdomen was distended and defense was present in the upper right quadrant and epigastrium. Rectum was empty at rectal examination; there was no bleeding and mass. 1000 cc intestinal contents were drained through naso-gastric catheter. Direct abdominal graph at standing position showed diffuse air-fluid levels (Figure 1).



Figure 1. Air-Fluid levels on plain abdominal graph.

Laboratory findings showed white blood cells: 16,400/L, urea 68 mg/dL, creatinine: 1.5 mg/dL, AST: 45 IU/L, ALT: 84 IU/L, total bilirubin: 1.2 mg/dL, direct bilirubin 0.41 mg/dL, sodium: 130 mmol/L, chloride: 91 mmol/L. The abdominal CT scan with IV/Oral contrast revealed that small bowels were dilated and wall thickness had increased (Figure 2a-b). Patient was diagnosed with mechanical small bowel obstruction and the decision was made to perform a laparotomy. Abdominal cavity was accessed through layers by making a midline incision. During the surgery, it was observed at 100 cm proximal to the ileocecal valve that ileum's anterior wall consisted of left mesocolon, was herniated to the duodenojejunal recessus and seen necrotic places in small intestine and mesocolon (Figure 3a-b). Hernia sac was opened into an avascular area, while the inferior mesenteric veins in the left mesocolon were preserved. Herniated bowel loops were reduced. Some necrotic areas were resected (0.5 to 1 cm) in small intestine and mesocolon and primary repaired as double layer. Recessus was closed with continuous non-absorbable sutures.

Patient was discharged on the ninth day following the operation.

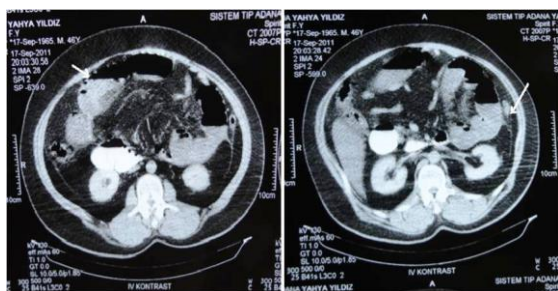


Figure 2. Dilated bowel loops with increased wall thickness (arrow) (A). CT image of jejunal loops adjacent to the left kidney, clustered in the tail section of pancreas (arrow) (B).

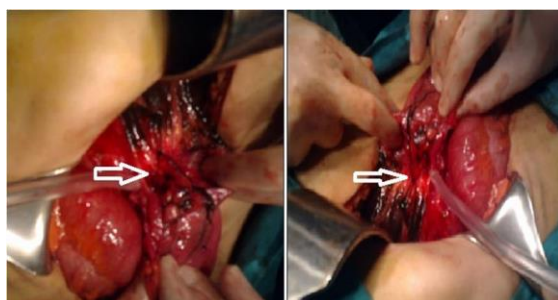


Figure 3. Surgery image of PDH with the anterior wall constituted of left mesocolon, which herniated to duodenojejunal recessus and were some necrotic areas(A,B).

Discussion

PDH was first reported to be caused by intestinal malrotations in 1935 by Callander et al. Later, Taylor et al. identified right PDH with radiological images².

PDH occurs between the fifth and eleventh weeks of gestational life, with the protrusion of small intestines or mesocolon into the apertures caused from the abnormal rotation of the midgut or incomplete fusion of mesos during organogenesis. Although this is a congenital condition it generally becomes symptomatic between the ages of 40 and 60^{2,3}.

PDH is largely asymptomatic but can feature symptoms such as cramping abdominal pain,

nausea and vomiting, distention and inability to pass flatus and stool. Such symptoms were present in our case^{3,4}. In the left PDH, jejunal loops were herniated, passing through the aperture on the left of the Treitz ligament. The left paraduodenal fossa was first described in 1871 by Landzert and is lateral to the fourth portion of the duodenum, posterior to inferior mesenteric vein and left colic artery. In the IH series of 467 cases by Hansmann and Morton, the left paraduodenal fossa was divided into 7 groups according to anatomic locations: paraduodenal, foramen Winslow, pericecal, intersigmoid, transmesenteric, transomental and retroanastomotic⁴.

In our case, hernia was in the left paraduodenal region.

In PDH, the hernia sac is usually comprised of small intestine loops and does not contain colon or omental tissue. The hernia sac can consist of a few centimeters long small bowel loops or may include all of the small intestine^{2,5}.

Radiological imaging techniques are not specific enough for making the diagnosis. Imaging of air-fluid levels in plain direct abdominal graphy may be helpful; however, it is not sufficient for differential diagnosis⁴. In contrast, a CT scan of the right PDH showed dilated bowel loops clustered in a sac. Left PDH is usually seen as an abnormal cluster behind the small intestine and stomach, on the left of the fourth portion of the duodenum^{2,4}. In our case, air-fluid levels were seen in X-Ray and small intestine was increased wall thickness and diameter in CT.

In un-operated on patients, transmesenteric, pericecal, foreman Winslow and omental hernias, perforation and tumors may be considered for differential diagnosis. Diagnosis is usually made during surgery^{3,4}. In half of the PDH cases, obstruction, incarceration and strangulation may be seen⁴⁻⁷. In our case, surgery was decided in consideration of possible complications. Our patient underwent an operation for the small bowel obstruction and the diagnosis of PDH was made during surgery.

The basic treatment principle of PDH is to reduce the protruded segment, expose normal anatomy and repair the defect. In surgical treatment of PDH, Davis et al. isolated the inferior mesenteric vein (IMV) through an incision made to the anterior wall of the hernia sac, just from the left side of the vein, and IMV was placed to the area created on the left of the duodenojejunal junction through an incision to the posterior peritoneum. Following that procedure, posterior parietal peritoneum ends were reciprocally re-sutured^{7,8}. In our case, the small intestine was necrosed approximately 1 cm on the antimesenteric side and the hernia sac that surrounds the small intestine was expanded by cutting. Herniated intestinal loops were reduced, preserving the inferior mesenteric vein. The defect on internal orifice was repaired. The patient had hypertension and obesity and due to the possibility of anastomotic leakage, necrotic areas were primarily repaired.

Recently, laparoscopic hernia repair in the treatment of PDH has begun to be performed, as demonstrated by Uematsu et al., who

performed a laparoscopic PDH repair successfully⁹. Additionally, Finck et al. laparoscopically repaired a paraduodenal hernia that was incidentally detected¹⁰.

Conclusion

Paraduodenal hernias constitute only a small portion of unoperated on small intestine obstructions. Paraduodenal hernias should be considered in patients diagnosed with small bowel obstruction but who do not have a history of previous surgery and when the underlying pathology is not able to be detected. The early diagnosis of PDH and the subsequent surgical treatment significantly decrease morbidity and mortality.

References

1. Seya T, Uchida E, Yokoi K et al. Left Paraduodenal Hernia Incidentally Diagnosed during Operation for Transverse Colon Cancer, Japan Med Nippon Sch 2010;77(2):111-114.
2. Yun MY, Choi YM, Choi SK et al. Left Paraduodenal Hernia Presenting with Atypical Symptoms Yonsei Med J 2010;51(5):787-789.
3. Borrscheid R, Shah S. Left Paraduodenal Hernia: Case Report and Literature Review, Eur J Surg Sci 2011;2(3):62-67.
4. Nuño-Guzmán CM, Arróniz-Jáuregui J, Hernández-González C et al. Right Paraduodenal Hernia in an Adult Patient: Diagnostic Approach and Surgical Management Case Rep Gastroenterol 2011;5:479-486.
5. Murray H. Left paraduodenal hernia. Canad MAJ 1955;72:263-267.
6. Acu R, Ölçer T, Küçükay F, ve ark. Sol paraduodenal herni: Çok kesitli bilgisayarlı tomografi bulguları, Akademik Gastroenteroloji dergisi, 2010;9(1):38-40. Filis K
7. Şen M, Bozer M, Dener C, ve ark. Ulus Travma Acil Cerrahi Derg 2007;13(3):232-236.
8. Kuzinkovas V, Haghighi K, Singha R, et al., Paraduodenal hernia: a rare cause of abdominal pain Canadian J Surg;2008;51(6):127-128.
9. Uematsu T, Kitamura H, Iwase M, et al. Laparoscopic repair of a paraduodenal hernia. Surg Endosc 1998;2:50-52.
10. Finck CM, Barker S. A novel diagnosis of left paraduodenal hernia through laparoscopy. Surg Endosc 2000;14:87.