



The Effect of Botulinum Toxin Application to the Muscles of the Upper Extremities on Forearm Muscle Thickness and Motor Recovery in Patients with Hemiplegia

Hemiplejili Hastalarda Üst Ekstremitte Kaslarına Botulinum Toksin Uygulamasının Ön Kol Kas Kalınlığı ve Motor İyileşme Üzerine Etkisi

© Serdar KILINÇ, © Hüseyin Avni OSAL

Bolu Abant İzzet Baysal University Faculty of Medicine, Department of Physical Medicine and Rehabilitation, Bolu, Türkiye

ABSTRACT

Aim: The aim of this study was to investigate the effects of botulinum toxin injection on upper extremity muscle thickness and motor recovery in stroke patients.

Materials and Methods: The study was conducted retrospectively. Twenty stroke patients (11 males, 9 females) who received botulinum toxin injections into the forearm muscles of the upper extremity were included in the study. Muscle thickness measurements, brunnstrom motor recovery stages, and modified Ashworth scale scores were assessed before and one month after botulinum toxin injection.

Results: There were no significant change in the brunnstrom upper extremity and hand stages before or after botulinum toxin application ($p>0.05$). No significant change in forearm muscle thickness was observed in measurements taken from the proximal third of the volar surface of the forearm before or after the injections ($p>0.05$). A significant decrease in spasticity levels was observed in wrist flexor group and finger flexor group muscles after botulinum toxin application ($p=0.001$).

Conclusion: The study shows that botulinum toxin reduces spasticity but has no effect on brunnstrom motor recovery and muscle thickness.

Keywords: Stroke, botulinum toxin injection, spasticity, muscle thickness, brunnstrom motor recovery stage

ÖZ

Amaç: Bu çalışmanın amacı, inme hastalarında botulinum toksin enjeksiyonunun üst ekstremitte kas kalınlığı ve motor iyileşme üzerine etkilerini araştırmaktır.

Gereç ve Yöntem: Çalışma retrospektif olarak yürütülmüştür. Üst ekstremitte ön kol kaslarına botulinum toksin enjeksiyonu uygulanan yirmi inme hastası (11 erkek, 9 kadın) çalışmaya dahil edilmiştir. Kas kalınlığı ölçümleri, brunnstrom motor iyileşme evreleri ve modifiye Ashworth Skalası skorları, botulinum toksin enjeksiyonundan önce ve bir ay sonra değerlendirilmiştir.

Bulgular: Botulinum toksin uygulamasından önce ve sonra brunnstrom üst ekstremitte ve el evrelerinde anlamlı bir değişiklik görülmemiştir ($p>0,05$). Enjeksiyonlardan önce veya sonra ön kolun volar yüzeyinin proksimal üçte birinden alınan ölçümlerde ön kol kas kalınlığında anlamlı bir değişiklik gözlenmedi ($p>0,05$). Botulinum toksin uygulamasından sonra el bilek fleksör grubu ve el parmak fleksör grubu kaslarının spastisite düzeylerinde anlamlı bir azalma gözlemlendi ($p=0,001$).

Sonuç: Çalışma, botulinum toksinin spastisiteyi azalttığını ancak brunnstrom motor iyileşmesi ve kas kalınlığı üzerinde bir etkisi olmadığını göstermektedir.

Anahtar Kelimeler: İnme, botulinum toksin enjeksiyonu, spastisite, kas kalınlığı, brunnstrom motor iyileşme evresi

Address for Correspondence: Serdar KILINÇ MD, Bolu Abant İzzet Baysal University Faculty of Medicine, Department of Physical Medicine and Rehabilitation, Bolu, Türkiye

E-mail: drserdarkilinc@hotmail.com **ORCID ID:** orcid.org/0000-0002-9951-5105

Received: 23.09.2025 **Accepted:** 22.01.2026 **Publication Date:** 16.06.2026

Cite this article as: Kılınç S, Osal HA. The Effect of botulinum toxin application to the muscles of the upper extremities on forearm muscle thickness and motor recovery in patients with hemiplegia. Nam Kem Med J. 2026;14(2):144-150



INTRODUCTION

Stroke is the second leading cause of death worldwide. It poses a significant risk of disability among survivors. It is particularly prevalent in developing countries¹. There are significant changes in muscle tone in patients after a stroke. Spasticity, which is defined as an increase in muscle tone depending on speed, is one of the most common conditions². Spasticity that occurs during patients' recovery from a stroke can help maintain limb functionality when it is at reasonable levels. However, if it becomes severe, it can lead to a deterioration in motor activity and limitations in daily life participation, as well as the development of various physical impairments³. There are many treatment options for spasticity. Botulinum toxin (BoNT-A) injection treatment is one of the preferred options⁴. When treating spasticity, the clinical presentation and functional impairments must be carefully evaluated in order to develop an appropriate management strategy. Treatment goals should be determined based on the patient's current clinical status and functional capacity². Opinions differ regarding the effects of BoNT-A injections on motor function during stroke rehabilitation.

A systematic review found that BoNT-A injections combined with post-stroke rehabilitation had a limited effect on motor function. Nevertheless, it has been suggested that BoNT-A could help to improve motor function⁵. A exploratory meta-analysis study involved 47 patients from two randomised trials who received BoNT-A injections for post-stroke spasticity. The study showed that reducing spasticity in the arm was significantly associated with improvement in motor function⁶. Shaw et al.⁷ reported that BoNT-A type A did not significantly improve upper extremity motor function one month after treatment for post-stroke spasticity. Another meta-analysis study, compiled from a limited number of studies investigating the effects of BoNT-A type A injections on muscle elasticity, muscle thickness, and structure, revealed a significant improvement in muscle elasticity as assessed by ultrasound in the short term. Furthermore, no significant difference was found in muscle structure (muscle thickness, pennation angle) in the short term. However, a decrease in normalized muscle volume was observed in the long term⁸. In a study by Picelli et al.⁹ examining the ultrasonographic features of the medial gastrocnemius muscle following BoNT-A treatment in post-stroke patients, no significant change in muscle thickness was observed after one month. However, some studies indicate a decrease in muscle mass in the early stages after BoNT-A injections. A study in rats found that a decrease in gastrocnemius muscle mass began in the second week after BoNT-A injections¹⁰. In a prospective study conducted on cerebral palsy patients who received BoNT-A injections for the first time, a decrease in gastrocnemius muscle volume was observed in all follow-ups at 4 weeks, 13 weeks, and 25 weeks¹¹. Another study by Tok et al.¹² evaluated the medial gastrocnemius muscle on the hemiplegic side and observed a reduction in muscle thickness two months after treatment. Similarly, Yi et al.¹³ observed a

decrease in medial gastrocnemius muscle thickness for up to 12 weeks following BoNT-A injection in children with spastic hemiplegic cerebral palsy.

The use of BoNT-A in the treatment of spasticity has been investigated in systematic review and meta-analysis studies containing many studies. However, these generally focus on the effectiveness of the treatment¹⁴⁻¹⁶. To our knowledge, no study has examined the effect of BoNT-A application on upper extremity forearm muscle thickness and motor recovery in stroke patients. The aim of this study was to investigate the early effects of BoNT-A injections on upper extremity forearm muscle thickness and motor recovery in stroke patients.

MATERIAL AND METHODS

This retrospective cross-sectional study was conducted in accordance with the Ethical Principles of the Declaration of Helsinki and was approved by the Bolu Abant İzzet Baysal University Clinical Research Ethics Committee (approval number: 2023/429, date: 19.12.2023). This study was registered as a clinical trial on ClinicalTrials.gov.

Selection and Description of the Cases

Patient charts were scanned to identify patients who were hospitalised for neurological rehabilitation at the Bolu Abant İzzet Baysal University Physical Medicine and Rehabilitation Training and Research Hospital between 1 January 2022 and 1 December 2023 and who received BoNT-A injections treatment. Twenty patients who met these criteria were identified and included in the study. All of the patients included were also receiving neurological rehabilitation.

Study inclusion criteria were as follows: patients with hemiplegia due to first stroke who had BoNT-A injections for spasticity in the upper extremity muscles (flexor carpi ulnaris, palmaris longus, flexor carpi radialis, pronator teres, flexor digitorum superficialis, flexor digitorum profundus); patients aged between 30 and 75; and patients who had been at least 3 months post-stroke. No upper limit has been set for the duration of the disease. Exclusion criteria were having a neurological disease other than stroke, malignancy, and having a preexisting musculoskeletal deformity or disease in the upper extremity of the patient who had received BoNT-A injections.

The patients received neurological rehabilitation including range of motion, strengthening, balance-coordination, and stretching exercises during the period between BoNT-A injections and a one-month follow-up. Rehabilitation sessions were held five days a week, with each session lasting one hour.

All of these patients gave informed consent before the BoNT-A injections.

Evaluation Parameters

Patient data were retrospectively retrieved from the hospital's medical record system.

Patients' demographic data, the names of the upper extremity muscles injected with BoNT-A, and the injection doses were recorded.

Information on the brunnstrom motor recovery stage of the upper extremity and hand, the spasticity level of the upper extremity muscles according to the modified Ashworth scale (MAS), and the thickness of the forearm muscles measured by ultrasound was obtained from medical records kept before and one month after BoNT-A injections. The reason for using the first month evaluation data is to examine early effects, as this is the period when the effect of BoNT-A is most pronounced.

Primary Outcomes

Brunnstrom Stage: It was used to evaluate motor recovery in the upper extremity, hand and lower extremity, and also to indicate which motor level the patient is at. The brunnstrom stage consists of six stages, each representing progressively improving movement patterns. Higher scores indicate better motor recovery¹⁷.

Muscle thickness measurements were performed using a Falcon 2101 EXL 2003 ultrasound device equipped with an 8 MHz linear probe, both before and one month after BoNT-A application.

In patients who received BoNT-A injections into the musculus (m) palmaris longus, m. pronator teres, m. flexor carpi radialis, m. flexor carpi ulnaris, m. flexor digitorum profundus, and m. flexor digitorum superficialis, muscle thickness was measured using ultrasound from the proximal one-third of the volar side of the forearm. Measurements were taken before and one month after the application. The forearm muscles were at rest during the measurements. Muscle thickness was recorded by measuring the vertical distance between the subcutaneous tissue and the radius and ulna bone borders on the ultrasound image. Two measurements were taken, radial and ulnar side, and recorded in millimeters (Figure 1). Ultrasound measurements showed good to excellent intra-rater reliability (intraclass correlation coefficient= 0.89; 95% confidence interval: 0.80-0.94).

Secondary Outcomes

MAS: It involves scoring the amount of resistance that specific muscle groups offer to passive movement by manually moving the extremity. A 5-stage scale has been defined to rate resistance during passive muscle tension. Higher scores indicate greater levels of spasticity¹⁸.

Statistical Analysis

For statistics the SPSS 23 program was used. The normality of the data was assessed using the Shapiro-Wilk test. The mean, standard deviation, frequency, median, minimum and maximum values were recorded. The Paired Samples t-test was used to compare normally distributed data, while the Wilcoxon Signed-Rank test was used to compare non-normally distributed data. A p-value of less than 0.05 was considered statistically significant.

RESULTS

In this retrospective cross-sectional study, 20 patients (11 males, 9 females) were included. The mean age of the patients was 60 years. Other demographic data are presented in Table 1. The muscles injected with BoNT-A and the mean dosages were indicated in the Table 2.

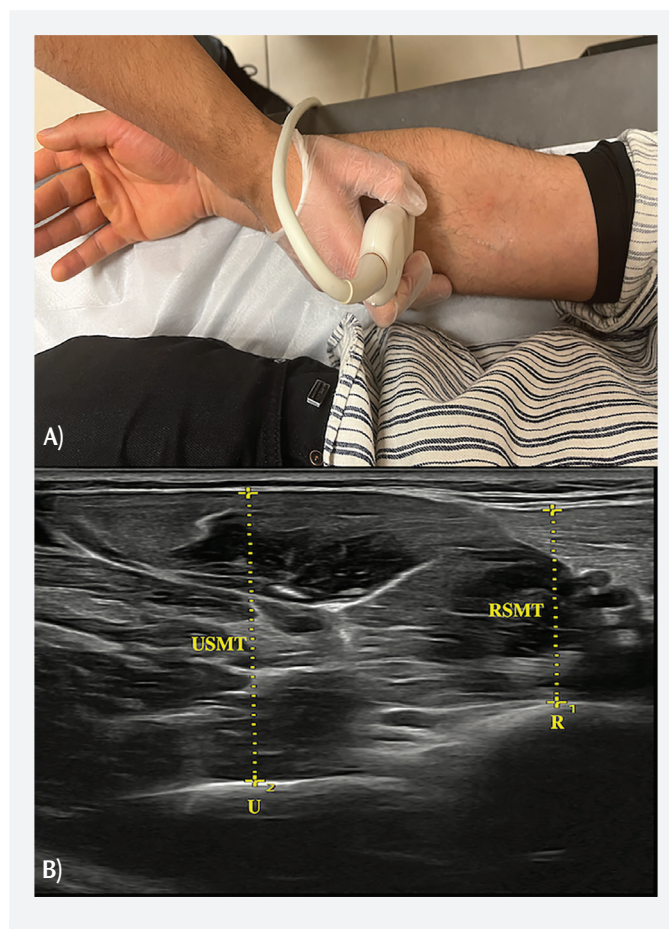


Figure 1. Images of the ultrasound scanning protocol

A) A linear ultrasound probe was placed in the proximal one-third of the volar side of the forearm for transverse scanning, B) To measure muscle thicknesses (RSMT, USMT), the callipers were placed between the bony cortex and the superficial muscle fascia

R: Radius; U: Ulna; RSMT: Radial side muscle thickness; USMT: Ulnar side muscle thickness

Muscle thickness measurements, brunnstrom stages, and MAS scores were assessed before and one month after BoNT-A injections.

There was no significant change in the brunnstrom upper extremity stage before or after BoNT-A application ($p>0.05$). Similarly, the brunnstrom hand stage did not show any significant change ($p>0.05$) (Table 3).

Table 1. Demographic data of patients	
	Mean ± SD (min-max)
Age (years)	60.0±8.58 (37-73)
Duration of disease (months)	59.10±59.36 (6-215)
	Frequency [n (%)]
Gender	
Male	11 (55%)
Woman	9 (45%)
Marital status	
Married	17 (85%)
Single	3 (15%)
Affected side	
Right	10 (50%)
Left	10 (50%)
Etiology of CVE	
Thromboembolism	14 (70%)
Hemorrhagic	6 (30%)

CVE: Cerebrovascular event, SD: Standard deviation

No significant change in muscle thickness was observed in measurements taken from the proximal third of the ulnar side of the volar surface of the forearm before or after the injections ($p=0.198$). Similarly, no significant change in muscle thickness was observed in measurements taken from the proximal third of the radial side of the volar surface of the forearm ($p=0.775$) (Table 3).

Wrist Flexor Group Muscles: A significant decrease in spasticity levels was observed in this muscle group after BoNT-A application ($p=0.001$).

Finger Flexor Group Muscles: Similarly, a significant decrease in spasticity levels was observed in this muscle group after treatment. ($p=0.001$) (Table 3).

Table 2. Muscles injected with botulinum toxin and dosages		
	Patients injected, n	Dosage IU (mean ± SD)
Flexor carpi ulnaris	20	26±2.05
Palmaris longus	18	24.7±1.18
Flexor carpi radialis	20	29.5±1.54
Pronator teres	20	30±0
Flexor digitorum superficialis	20	26.2±2.20
Flexor digitorum profundus	20	26.2±2.20

IU: International unit, SD: Standard deviation

Table 3. Comparison of the forearm muscle thickness, motor recovery and spasticity of patients before and one month after a botulinum toxin injections					
	Before botulinum toxin application	After botulinum toxin application	Mean difference	(95% CI)	p-value*
	Mean ± SD	Mean ± SD			
Muscle thickness of the forearm/mm					
Ulnar side (mm)	32.2±4.8	31.6±4.4	0.76	-0.29-1.82	0.198
Radial side (mm)	17.6±3.5	17.4±3.0	0.12	-0.75-1.00	0.775
	Median (min-max)	Median (min-max)	p-value**		
Motor recovery					
Brunnstrom upper extremity	3 (2-5)	3 (2-5)	0.157		
Brunnstrom hand	3 (2-4)	3 (2-4)	0.083		
Spasticity					
MAS of the wrist flexor group muscles	3 (1-4)	3 (1-4)	0.001		
MAS of the finger flexor group muscles	4 (1-4)	3 (1-4)	0.001		

*The Paired Samples t-test was applied, **Wilcoxon Signed-Rank test was applied, mm: Millimeters, MAS: Modified Ashworth scale, CI: Confidence interval, SD: Standard deviation

DISCUSSION

This study found that injecting BoNT-A into the upper extremity muscles of stroke patients significantly reduced spasticity after a 1-month follow-up, but did not significantly affect motor recovery or muscle thickness.

The use of BoNT-A the treatment of post-stroke spasticity is widely accepted in the literature^{19,20}. A study by Sun et al.¹⁴ demonstrated that BoNT-A was superior to placebo in reducing upper or lower limb spasticity after stroke. In a study conducted by Varvarousis et al.¹⁹, which evaluated lower limb spasticity (using MAS) and gait pattern (10-metre walk test) after stroke, it was observed that BoNT-A reduced the degree of lower limb spasticity. In this recent study, a significant decrease was observed in wrist and finger flexor spasticity levels, as assessed by MAS, in patients treated with BoNT-A.

Studies investigating the effects of BoNT-A on motor function have produced mixed results. While some studies indicate that BoNT-A has a positive effect on improving motor function^{21,22}, others suggest that it has no significant effect^{23,24}. In a study by Lim et al.²⁵ comparing the effects of BoNT-A injections in subacute and chronic stroke patients, no change was observed in brunnstrom stages in either group, while an improvement was observed in Fugl-Meyer scores. In a study by Devier et al.²⁶, an improvement in motor function was observed in patients receiving rehabilitation alongside BoNT-A treatment for chronic upper extremity spasticity following a stroke. In a study by Çelebi et al.²⁷ investigating the effects of ultrasound-guided BoNT-A injections on pain, functionality, spasticity, and range of motion in patients with upper extremity spasticity following a stroke, motor function was evaluated using the Fugl-Meyer scale at the second week and third month of treatment. It was observed that motor function had improved significantly. In a study by Hesse et al.²⁸ investigating the effects of BoNT-A injections treatment for upper extremity spasticity within 12 weeks of a stroke, no significant change in motor function values was observed when evaluated using the modified Rankin Scale and the Motor Function Assessment scale. In Hesse et al.²⁸ study examining the effect of early BoNT-A treatment on finger flexors six weeks after subacute stroke, arm motor function was evaluated using the Fugl-Meyer scale, and no significant change was observed. In our study, no significant change in motor function recovery was observed. This result is consistent with some previous studies and shows that BoNT-A has a limited effect on motor function. As the patients in this study were chronic stroke patients, no change may have been observed in their Brunnstrom motor recovery stages after BoNT-A. Furthermore, brunnstrom staging may not be the optimal method for assessing motor recovery after BoNT-A application. Although frequently used to assess motor recovery, it may be insufficient in capturing minor functional changes

and fine motor movements outside of synergy in the patient. More detailed scales such as Fugl-Meyer may yield different results.

The effect of BoNT-A on muscle thickness has been investigated mostly in lower extremity muscles, and there are limited studies in the literature. No significant changes were observed in the ultrasonographic features of the muscle 4 weeks after BoNT-A injections into the gastrocnemius medialis and lateralis muscles due to spastic equinus in stroke patients¹¹. However, there are studies showing that the thickness of the gastrocnemius muscle decreases 2 months after BoNT-A administration in stroke patients and approximately 4 weeks after BoNT-A administration in patients with cerebral palsy^{12,13}. However, no significant change in muscle thickness was observed in our study due to BoNT-A. The main difference between this study and other studies is the evaluation of the upper extremity muscles. While upper limb muscles are subjected to short bursts of low-intensity activity throughout the day, lower limb muscles require stronger contractions to maintain body balance²⁹. The lower limb muscle architecture has a wide pennate angle, allowing for greater force generation³⁰. However, age-related sarcopenia has been found to be more severe in lower extremity muscles than in upper extremity muscles³¹. These differences between upper and lower limb muscles may have differentiated the effect of BoNT-A injections on muscle thickness.

Repeated BoNT-A administration has been shown to cause muscle volume reduction and fibrosis over time in the masseter muscle and in experimental animals^{32,33}. Ultrasonographic examinations in stroke patients revealed decreased muscle thickness in the spastic extremity compared to the contralateral muscles³⁴. Another study found that spastic muscles were thinner than non-spastic muscles, but no significant differences were found in muscle and fascial properties between the spastic flexor carpi ulnaris with and without BoNT-A injections³⁵.

A review has indicated that repeated BoNT-A injections can cause permanent muscle atrophy and negatively impact BoNT-A long-term effectiveness. Therefore, it has been emphasized that further studies examining the muscle properties of BoNT-A-treated muscles are needed, and that this monitoring can be achieved especially through ultrasound, a non-invasive method³⁶. In summary, the present study adds to the limited evidence on early changes in muscle thickness and motor recovery at the 1-month follow-up BoNT-A treatment in stroke patients.

Study Limitations

One of the limitations of this study is that the number of patients is low, and the etiology is not uniform. The small sample size and the retrospective nature of the study limit the generalizability of the findings. Due to the limited sample

size, the study may have been underpowered to detecting small effects, especially changes in muscle thickness. The short follow-up period (1 month) and the application of only a single dose of BoNT-A injection do not allow the evaluation of the long-term effects of the treatment. Due to the retrospective design of the study, there was insufficient data available on patient evaluations from the second or third month. This is one of the study's limitations, as it does not reflect the medium- and long-term effects of BoNT-A. Therefore, long-term studies with larger samples, prospective designs and repeated injections are needed to evaluate the long-term effects of BoNT-A more accurately. In addition to evaluating muscle thickness using ultrasound, we suggest evaluating muscle volume using magnetic resonance imaging in future studies.

CONCLUSION

The study shows that BoNT-A reduces spasticity after a 1-month follow-up, significant changes in motor recovery and muscle thickness were not observed.

Ethics

Ethical Committee Approval: The Ethical Principles of the Declaration of Helsinki and was approved by the Bolu Abant İzzet Baysal University Clinical Research Ethics Committee (approval number: 2023/429, date: 19.12.2023).

Informed Consent: This retrospective cross-sectional study.

Footnotes

Authorship Contributions

Surgical and Medical Practices: S.D., Concept: S.D., Design: S.D., Data Collection or Processing: S.D., H.A.O., Analysis or Interpretation: S.D., H.A.O., Literature Search: S.D., H.A.O., Writing: S.D., H.A.O.

Conflict of Interest: No conflict of interest was declared by the authors.

Financial Disclosure: The authors declared that this study received no financial support.

REFERENCES

- Kuriakose D, Xiao Z. Pathophysiology and treatment of stroke: present status and future perspectives. *Int J Mol Sci.* 2020;21:7609.
- Francisco GE, Wissel J, Platz T, Li S. Post-Stroke Spasticity. Clinical pathways in stroke rehabilitation: evidence-based clinical practice recommendations [Internet]. Cham (CH): Springer; 2021.
- Khan F, Amatya B, Bensmail D, Yelnik A. Non-pharmacological interventions for spasticity in adults: an overview of systematic reviews. *Ann Phys Rehabil Med.* 2019;62:265-73.
- Li S, Francisco GE. The use of botulinum toxin for treatment of spasticity. *Handb Exp Pharmacol.* 2021;263:127-46.
- Hara T, Momosaki R, Niimi M, Yamada N, Hara H, Abo M. Botulinum toxin therapy combined with rehabilitation for stroke: a systematic review of the effect on motor function. *Toxins (Basel).* 2019;11:707.
- Francis HP, Wade DT, Turner-Stokes L, Kingswell RS, Dott CS, Coxon EA. Does reducing spasticity translate into functional benefit? An exploratory meta-analysis. *J Neurol Neurosurg Psychiatry.* 2004;75:1547-51.
- Shaw L, Rodgers H, Price C, van Wijck F, Shackley P, Steen N, et al. BoTULS: a multicentre randomised controlled trial to evaluate the clinical effectiveness and cost-effectiveness of treating upper limb spasticity due to stroke with botulinum toxin type A. *Health Technol Assess.* 2010;14:1-113.
- Devis M, Lecouvet F, Lejeune T, Stoquart G. Noninvasive analysis of overactive muscle structure and elasticity after botulinum toxin type a injection: a systematic review and meta-analysis. *Eur J Phys Rehabil Med.* 2024;60:567-80.
- Picelli A, Filippetti M, Melotti C, Guerrazzi F, Modenese A, Smania N. Does botulinum toxin treatment affect the ultrasonographic characteristics of post-stroke spastic equinus? A retrospective pilot study. *Toxins (Basel).* 2020;12:797.
- Ma J, Elsaidi GA, Smith TL, Walker FO, Tan KH, Martin E, et al. Time course of recovery of juvenile skeletal muscle after botulinum toxin a injection: an animal model study. *Am J Phys Med Rehabil.* 2004;83:774-83.
- Alexander C, Elliott C, Valentine J, Stannage K, Bear N, Donnelly C, et al. Muscle volume alterations after first botulinum neurotoxin a treatment in children with cerebral palsy: a 6-month prospective cohort study. *Dev Med Child Neurol.* 2018;60:1165-71.
- Tok F, Ozçakar L, Safaz I, Alaca R. Effects of botulinum toxin-a on the muscle architecture of stroke patients: the first ultrasonographic study. *J Rehabil Med.* 2011;43:1016-9.
- Yi YG, Jang DH, Lee D, Oh JY, Han MH. Botulinum toxin injection in children with hemiplegic cerebral palsy: correction of growth through comparison of treated and unaffected limbs. *Toxins (Basel).* 2019;11:688.
- Sun LC, Chen R, Fu C, Chen Y, Wu Q, Chen R, et al. Efficacy and safety of botulinum toxin type a for limb spasticity after stroke: a meta-analysis of randomized controlled trials. *Biomed Res Int.* 2019;2019:8329306.
- Baker JA, Pereira G. The efficacy of botulinum toxin a for spasticity and pain in adults: a systematic review and meta-analysis using the grades of recommendation, assessment, development and evaluation approach. *Clin Rehabil.* 2013;27:1084-96.
- Guyot P, Kalyvas C, Mamane C, Danchenko N. Botulinum toxins type A (BoNT-A) in the management of lower limb spasticity in children: a systematic literature review and Bayesian network meta-analysis. *J Child Neurol.* 2019;34:371-81.
- Sawner KA, LaVigne JM, Brunnstrom S. Brunnstrom's movement therapy in hemiplegia : a neurophysiological approach. Philadelphia: Lippincott. 1992.
- Li F, Wu Y, Li X. Test-retest reliability and inter-rater reliability of the Modified Tardieu scale and the modified Ashworth scale in hemiplegic patients with stroke. *Eur J Phys Rehabil Med.* 2014;50:9-15.
- Varvarousis DN, Martzivanou C, Dimopoulos D, Dimakopoulos G, Vasileiadis GI, Ploumis A. The effectiveness of botulinum toxin on spasticity and gait of hemiplegic patients after stroke: a systematic review and meta-analysis. *Toxicon.* 2021;203:74-84.
- Picelli A, Santamato A, Cosma M, Baricich A, Chisari C, Millevolte M, et al. Early botulinum toxin type a injection for post-stroke spasticity: a longitudinal cohort study. *Toxins (Basel).* 2021;13:374.
- Uchiyama Y, Koyama T, Wada Y, Katsutani M, Kodama N, Domen K. Botulinum toxin type a treatment combined with intensive rehabilitation for gait poststroke: a preliminary study. *J Stroke Cerebrovasc Dis.* 2018;27:1975-86.
- Prazeres A, Lira M, Aguiar P, Monteiro L, Vilasbôas Í, Melo A. Efficacy of physical therapy associated with botulinum toxin type a on functional performance in post-stroke spasticity: a randomized, double-blinded, placebo-controlled trial. *Neurol Int.* 2018;10:7385.

23. Demetrius M, Gorelik A, Louie J, Brand C, Baguley IJ, Khan F. Outcomes of ambulatory rehabilitation programmes following botulinum toxin for spasticity in adults with stroke. *J Rehabil Med*. 2014;46:730-7.
24. Rosales RL, Kong KH, Goh KJ, Kumthornthip W, Mok VC, Delgado-De Los Santos MM, et al. Botulinum toxin injection for hypertonicity of the upper extremity within 12 weeks after stroke: a randomized controlled trial. *Neurorehabil Neural Repair*. 2012;26:812-21.
25. Lim YH, Choi EH, Lim JY. Comparison of effects of botulinum toxin injection between subacute and chronic stroke patients: a pilot study. *Medicine (Baltimore)*. 2016;95:e2851.
26. Devier D, Harnar J, Lopez L, Brashear A, Graham G. Rehabilitation plus onabotulinumtoxinA improves motor function over onabotulinumtoxinA alone in post-stroke upper limb spasticity: a single-blind, randomized trial. *Toxins (Basel)*. 2017;9:216.
27. Çelebi G, Ayyıldız A, Çiftci Inceoğlu S, Kuran B. The effect of ultrasound-guided botulinum toxin injections on pain, functionality, spasticity, and range of motion in patients with post-stroke upper extremity spasticity. *Rehabilitacion (Madr)*. 2025;59:100876.
28. Hesse S, Mach H, Fröhlich S, Behrend S, Werner C, Melzer I. An early botulinum toxin a treatment in subacute stroke patients may prevent a disabling finger flexor stiffness six months later: a randomized controlled trial. *Clin Rehabil*. 2012;26:237-45.
29. Lieber RL, Fridén J. Functional and clinical significance of skeletal muscle architecture. *Muscle Nerve*. 2000;23:1647-66.
30. Ruggiero M, Cless D, Infantolino B. Upper and Lower limb muscle architecture of a 104 year-old cadaver. *PLoS One*. 2016;11:e0162963.
31. Janssen I, Heymsfield SB, Wang ZM, Ross R. Skeletal muscle mass and distribution in 468 men and women aged 18-88 yr. *J Appl Physiol*. 2000;89:81-8.
32. Koo HJ, Hu H, Kim W, Kim JS, Kim HJ, Yi KH. Do repetitive botulinum neurotoxin injections induce muscle fibrosis? Sonographic observation of the masseter muscle. *J Cosmet Dermatol*. 2024;23:434-40.
33. Fortuna R, Vaz MA, Youssef AR, Longino D, Herzog W. Changes in contractile properties of muscles receiving repeat injections of botulinum toxin (Botox). *J Biomech*. 2011;44:39-44.
34. González-Buonomo J, Pham AH, Ghuman J, Malik A, Yozbatiran N, Francisco GE, et al. Ultrasound assessment of spastic muscles in ambulatory chronic stroke survivors reveals function-dependent changes. *J Rehabil Med*. 2023;55:jrm00342.
35. Agat EM, Horstmann K, Francisco GE, Li S. Ultrasound assessment of muscle and fascia properties and the effects of spasticity and botulinum toxin injections on spastic muscles in chronic stroke survivors. *Am J Phys Med Rehabil*. 2025;104:527-33.
36. Mathevon L, Michel F, Decavel P, Fernandez B, Parratte B, Calmels P. Muscle structure and stiffness assessment after botulinum toxin type A injection: a systematic review. *Ann Phys Rehabil Med*. 2015;58:343-50.